



Dental Clinics,

attached with wings
of digital.

Predictability

Operation result can be predicted through precision diagnostics with digital devices and 3D simulated operation.

Top-Down Prosthesis Load Stress Reduction

Through the top-down approach prosthesis designs and implant positioning having considered occlusion and load distribution you can expect to achieve less stress on the crowns and longevity of the implant.

Expanded Range of Operation

The case such as sinus lift, immediate implant after extraction, edentulous cases are available.

Save the Operation Time

Save the operation time by eliminating processes such as incisions and sutures and resolving the concerns about implant positioning.



Patients,

attached with wings
of comfort.

Comfortable Operation

No Water. No Noise.
No Incision. No Heating

Reduce Pain with Minimal Incision


Minimal Incision reduces pain and minimizes bleeding, swelling. It enables rapid recovery

Available for Patients with Systemic Diseases

With minimizing bleeding due to minimal incision, the operation possibility of patients with systemic diseases patient is increased.

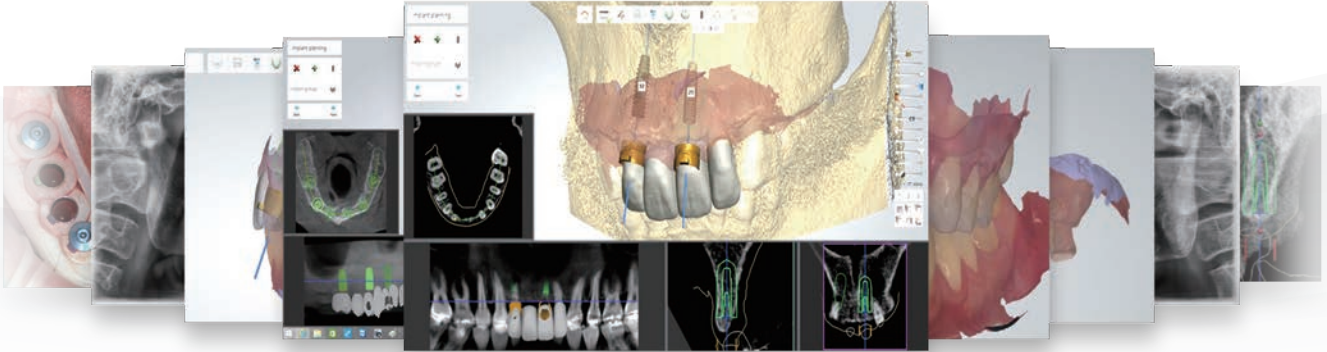
Returning to daily Life Quickly

Depending on the case, an immediate temporary crown can be placed and it allows the patient to return to daily life quickly.



What? is different

DIVERSE INDICATION



Provides perfect solutions to different cases

Metal Artifact | Small Interdental Space Case | Narrow Ridge Case | Limited Mouth Opening
Edentulous | Immediate Placement on the Extraction Socket | Free End Case
Provisional Restoration on Subcrestal Level Implant | Sinus Lift

HIGH ACCURACY

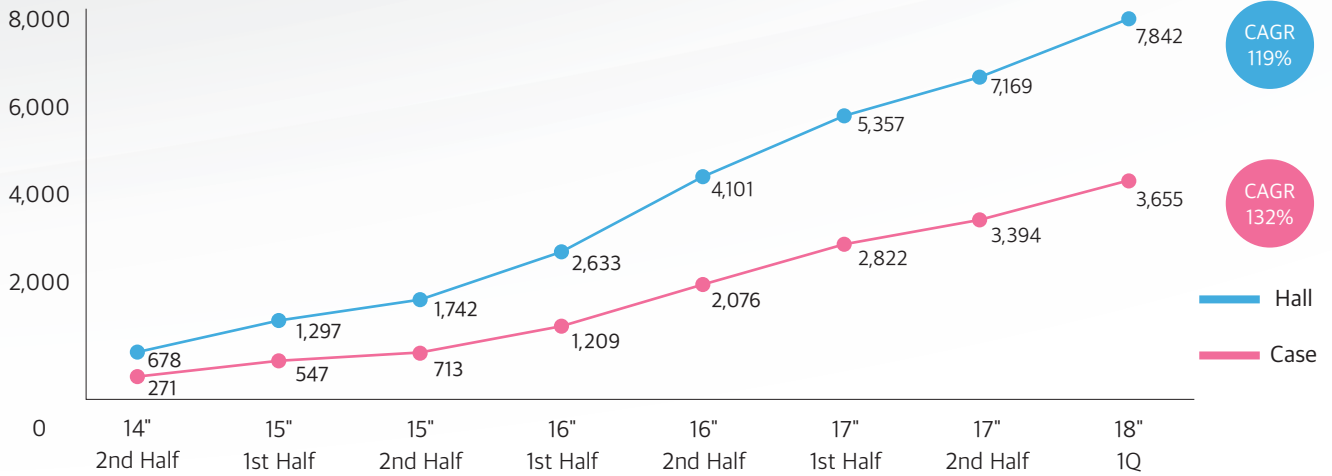
The entire process from diagnosis to implantation is proceeded with digitized data, eliminating the hassle and error incurred in the analog system



• DIONavi. Full Digital Horizontal Error (In Vitro) : Average 0.26 degrees

VERIFIED GUIDE SYSTEM

Usage trend (monthly average) of DIONavi.



Used for over 150,000 implant placements (2018.3)

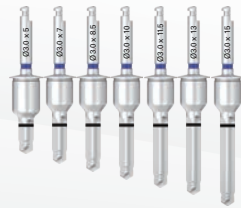Introduced at 2,000 clinics throughout the world

MORE DELICACY

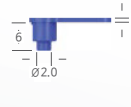
- Drilling of different lengths - **Accuracy + Safety UP** & Slip prevention tool



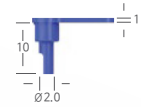
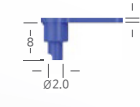| Drilling of different lengths |



| Bone Flattening Drill |



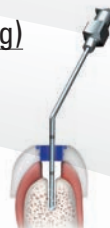| Ø2.0 Drill Tube |



- Low speed drilling and stepwise injection (**prevents bone heating**)

50RPM

Heat reduced by low speed drilling,
noise reduced by no injection

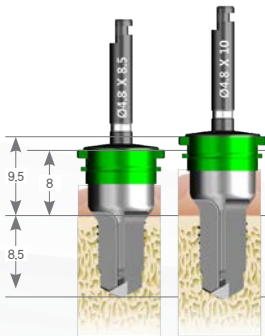


Prevents bone heating and removes
particles in bone cavity by injection in
each drill stop
(after removal of drill)

HOW you solve?

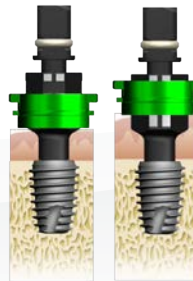
• Limited Mouth Opening

01 Use a wide sleeve and Wide-only Kit.



Method of selecting the drill according to sleeve offset (For 8.5mm drill)

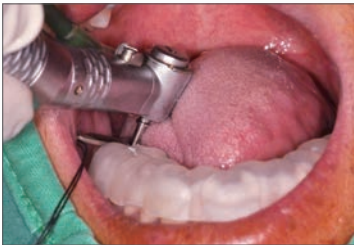- _ In case of 8mm offset
Select 8.5mm drill
- _ In case of 9.5mm offset
(Increased by 1.5mm)
Select 10mm drill



Reference height of the implant connector according to sleeve offset (For 8.5mm drill)

- _ In case of 8mm offset
To the first mark
- _ In case of 9.5mm offset
(increased by 1.5mm)
To the second mark

02



The burden of height can be reduced by carrying the $\varnothing 2.0 \times 5$ mm drill inserted into the drill tube from the outside of the patient's mouth to the guide hole.

03




Start with a short drill and sequentially increase length to 5, 7 and 10mm without using a drill tube.

• Immediate Placement on Extraction Socket

01

[ISD 2005M] [ISD 2007M] [ISD 2010M]



The $\varnothing 2.0$ initial drill connected to the drill tube allows for stable drilling with stable fixing force. Error range can be minimized by sequentially increasing length of the drill, starting with a short drill.

[USD 2705] [USD 2707] [USD 2710]




Select a short drill of $\varnothing 2.7$ to secure fixing force of the guide sleeve.

02


The $\varnothing 2.5$ point straight drill in Special Kit is an exclusive drill designed to prevent slipping.



Short Long



Drill slipping could be happened



Stable drilling when point straight drill is used

- **Metal Artifact**

Difficulty of data matching due to CT scattering

- **Free End Case**

Difficulty of matching implant site /
Difficulty of bite taking

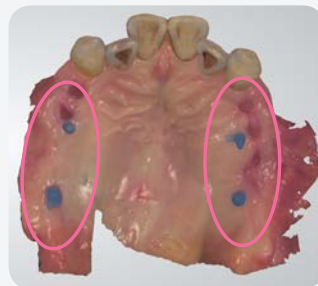
- **Edentulous Case**

Use of half-digital with plaster case because of no data matching (reduced accuracy)

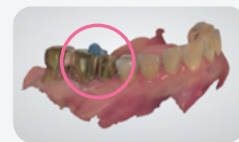Image	Name
	Marker CODE : SGM 5040
	Flow resin (radiopacity) (CHARMFIL BLUE resin recommended) CODE : ORCFFB 01

When attaching marker

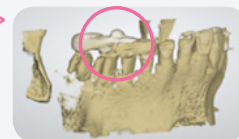It can be attached easily by using medical adhesive (Histoacryl)
CODE : 1050060
and flow resin (Charmfil).



< Free End



Metal Artifact >



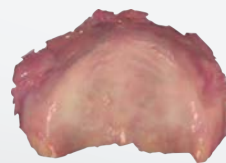Scan Retractor

Fully Digitalization Workflow for Edentulous Case

Upper jaw

Lower jaw

Before using scan retractor



Difficulty of checking boundary of attached gingiva and alveolar mucosa



Cannot use oral scan due to movement of tongue

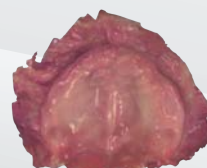
After using scan retractor



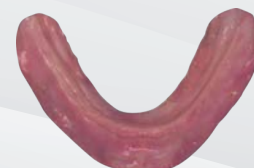Upper jaw
CODE: SCANR 01S



Lower jaw
Code: SCANR 02S




Accurate recognition of upper jaw opening, control of tongue movement (lower jaw), reference point of oral scan



Digital Implant DIONavi.
Line-Up DIONavi.




Fixture Size	Narrow		Regular					Wide		
DIONavi. Sleeve Size	Narrow		Standard				Wide		X	
	3.0	3.3	3.8	4.0	4.5	5.0	5.5	6.0	6.5	7.0



Standard Case

DIONavi. Master Kit
 Off-Set height : 9 / 10.5 / 12mm




Wide Case

DIONavi. Wide Kit
 Case with small mouth opening / Case with posterior region
 Off-Set height : 8 / 9.5mm



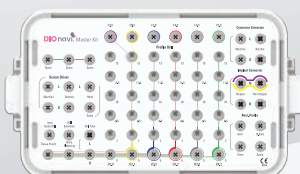
Narrow Case

DIONavi. Narrow Kit
 Case with narrow bones / Case with narrow interdental space
 Off-Set height : 12mm



Sinus Case

DIONavi. Master Kit &
 DIONavi. Sinus Crestal Approach Kit
 Hydraulic sinus lifting kit

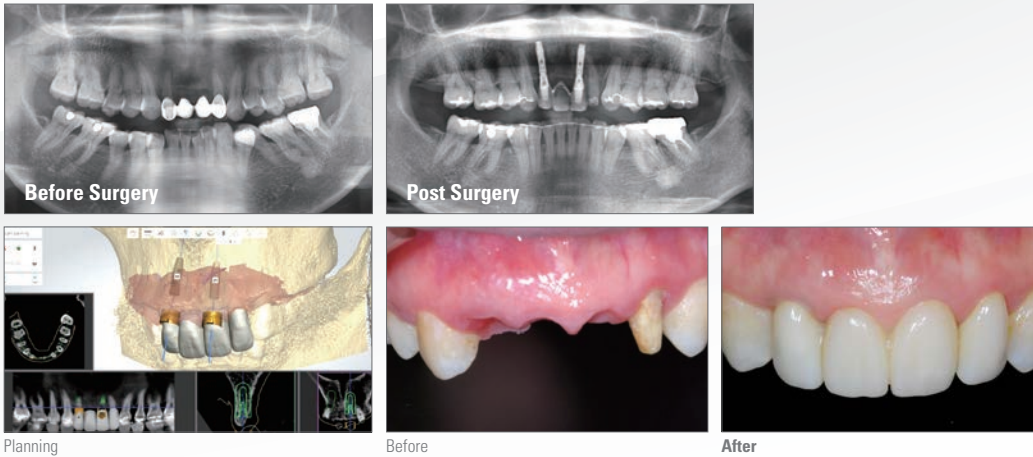


Edentulous Case

DIONavi. Master Kit & DIONavi. Special Kit
 Free end case / Case of immediate implantation
 after tooth extraction Including 15mm final drill

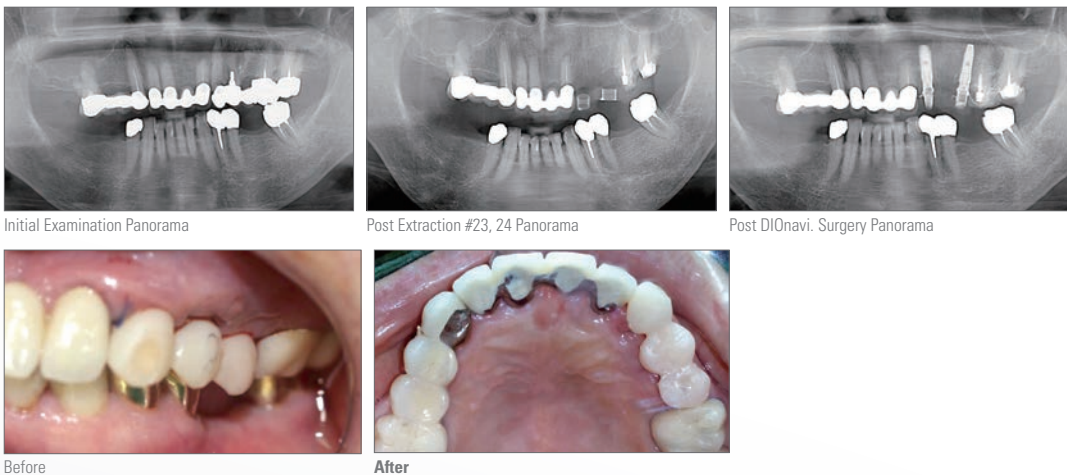
Minimally invasive implant placement using DIONavi. surgery

Dr. Kang Jae Seok, Clinical Director at Yedam Dental Clinic



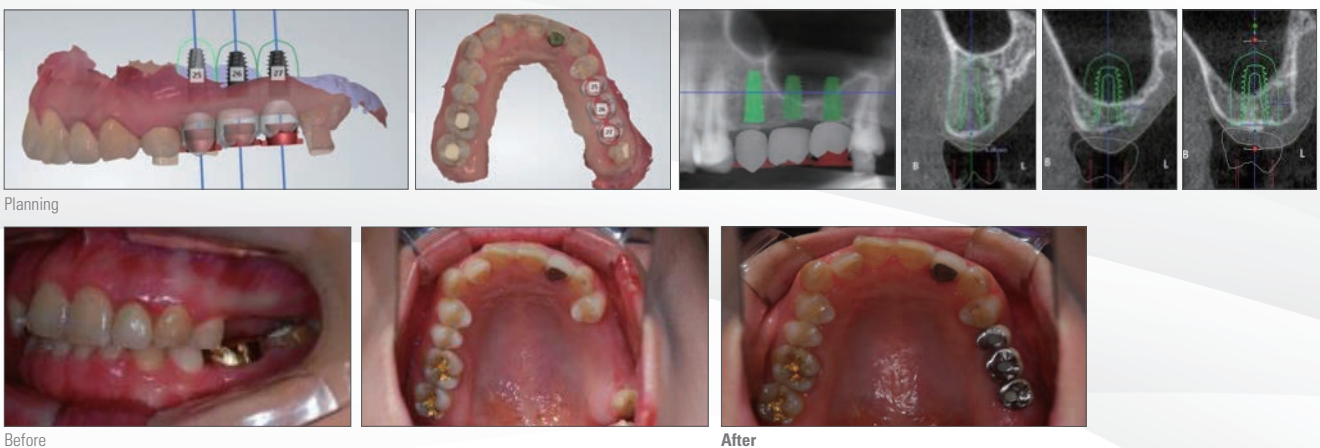
Minimally Invasive Tooth Extraction Accompanied By Bone Graft and Immediate Implant Placement

Dr. Lee Hyang Yeon, Clinical Director Michigan Dental Clinic



Sinus Lift Surgery Using CBCT Surgical Guide and Water Pressure

Dr. Choi Sung Ouk, Clinical Director Apple Tree Dental Clinic



Accuracy assessment of implant placement using a stereolithographic surgical guide made with digital scan

Source: Journal of Korean Academy of Prosthodontics, Vol. 53 (2015)

Seung-Mi Jeong^{1*}, Jeong-Whan Fang¹, Chan-Hyeon Hwang, Se-Ha Kang¹, Byung-Ho Choi², Yiqin Fang², Hyongtae Jeon³, Sunghun An³

¹Department of Prosthodontics, ²Department of Oral and Maxillofacial Surgery, Wonju College of Medicine, Yonsei University, Wonju, Republic of Korea

³Researcher, DIO research institute, Pusan, Republic of Korea

Purpose: The objective of this study was to evaluate the accuracy of a stereolithographic surgical guide that was made with information from intraoral digital impressions and cone beam CT (CBCT). **Materials and methods:** Six sets of resin maxilla and mandible models with missing teeth were used in this study. Intraoral digital impressions were made. The virtual models provided by these intraoral digital impressions and by the CBCT scan images of the resin models were used to create a surgical guide. Implant surgery was performed on the resin models using the surgical guide. After implant placement, the models were subjected to another CBCT scan to compare the planned and actual implant positions. Deviations in position, depth and axis between the planned and actual positions were measured for each implant. **Results:** The mean deviation of the insertion point and angulation were 0.28 mm and 0.26°, apex point were 0.11 mm and 0.14 mm respectively. The implants were situated at a mean of 0.44 mm coronal to the planned vertical position. **Conclusion:** This study demonstrates that stereolithographic surgical guides created without the use of impressions and stone models show promising accuracy in implant placement. (J Korean Acad Prosthodont 2015;53:)

Key words: CAD/CAM; Digital data; Digital impression; Digital implant; Guided surgery

Introduction

Digital computer-guided implant placement is a method of using digital scanned image and CBCT image

to determine the position and angle of an implant, make a surgical guide that contains information about the position and angle of the implant, and perform implant placement using this guide.

This method not only considers shape of bones but allows implant placement in a position appropriate for prosthetic treatment. Prosthesis to be placed on top of implant is designed before the surgery and made using CAD/CAM, so it can be attached immediately after implant placement.

Also, there is an advantage of being able to perform flapless implant placement using a surgical guide.

The flapless surgery reduces bleeding during surgery and pain and discomfort after surgery. If an abutment is attached immediately, the wound can hardly be seen to improve esthetic quality of the prosthesis and shorten the healing period.^{1,2}

Since the flapless surgery is a blind surgery that places implant through a small entrance formed on the gingiva without seeing the alveolar bone, it would be desirable to use a surgical guide with reliable accuracy. ³ Discrepancy of the surgical guide refers to the difference between position of implant planned out before the surgery and actual position of implant in the patient's mouth. According to literature review on discrepancy of the surgical guide, average position displacement

*Corresponding Author: Seung-Mi Jeong
Department of Prosthodontics, Wonju College of Medicine, Yonsei University, 20
Ilsan-ro, Wonju 220-701, Republic of Korea
+82 33 741 2114 : e-mail, smj3@yonsei.ac.kr
Article history: Received January 13, 2015 / Last Revision February 16, 2015 /
Accepted March 2, 2015

© 2015 The Korean Academy of Prosthodontic
© This is an Open Access article distributed under the terms of the Creative
Commons Attribution Non-Commercial License (<http://creativecommons.org/licenses/by-nc/3.0>) which permits unrestricted non-commercial use, distribution,
and reproduction in any medium, provided the original work is properly cited.

※ This work was supported by a research grant from Yonsei University Wonju College of medicine (YUWCM-2008-25). pISSN 0301-2875 , eISSN 2005-3789

was 1.22mm at the top of implant and 1.51mm at the bottom of implant. Average angle error was 4.9°, and maximum error was 15.3°. 4-9 Angle error of 15° is a value that can inflict critical damage on the adjacent anatomical structure. Surgical guides reported in the existing studies mostly involved the method of manually making a radiation guide and converting it into a surgical guide (manual method) or the method of manually making a radiation guide and turning it into a surgical guide by stereolithography.⁴⁻⁷ In this study, a surgical guide was designed using digital scanned image of the mouth and CBCT image without using impression material and plaster model, and the surgical guide was made using CAD/CAM. This surgical guide was used for accuracy assessment of dental implant.

Materials and Methods

1. Experimental Model

Six sets of partial edentulous maxilla and mandible models were used. The maxilla model was missing the central incisor, and the mandible model was missing the 1st and 2nd molar teeth on both sides (Fig. 1). The parts with missing teeth were covered with silicon gum of 2mm thickness, and the alveolar bone was manufactured using a wooden material of D1 bone quality.

2. Experimental Method

The model was regarded as the oral structure of the patient, and digital impression of the partial edentulous model was taken (Fig. 2, Fig. 3) using an oral scanner (TRIOSTM, 3Shape, Inc., Copenhagen, Denmark). The reference plate made for accuracy assessment of the surgical guide was used during CBCT imaging. The reference plate has 17 gutta-percha markers of 1mm diameter, and three markers were made to draw coordinate axes on X axis and Y axis.

The red lines in the figure are lines that indicate X axis and Y axis (Fig. 4). This plate is used to assess position of implant before and after the surgery. CBCT imaging was done after fixing the reference plate onto the occlusal surface of the model (Fig. 5).

The image file obtained from CBCT and the image file from digital impression were transmitted to an implant diagnostic software program (Implant Studio™, 3Shape, Inc., Copenhagen, Denmark) and matched. Position of implant was diagnosed and the surgical guide was designed based on the matching image of the two images (Fig. 6, Fig. 7).

The image of the surgical guide was printed using a 3D printer (ProJet 3510 MP, 3D Systems, SC, USA) to make the actual surgical guide (Fig. 8).

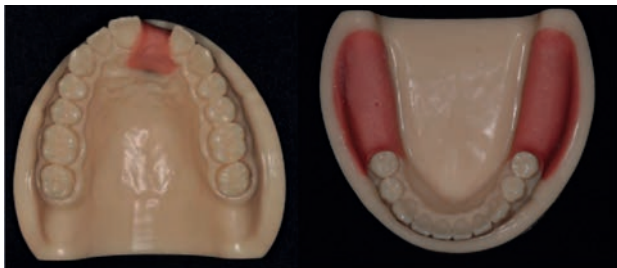

Fig. 1. Resin maxilla and mandible model with artificial silicone gums.

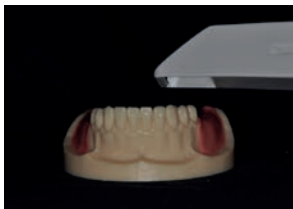

Fig. 2. Intraoral scanning of the resin model.

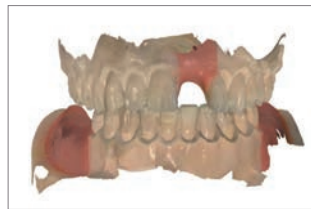

Fig. 3. Scanned model.

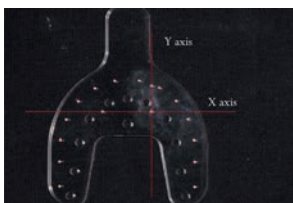


Fig. 4. Plastic plate for determination of a reference plane.

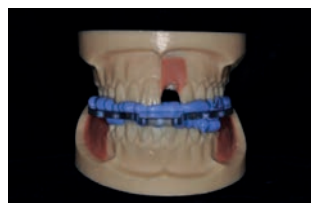

Fig. 5. Plastic plate attached to the resin model.

3. Implant Placement Using Surgical Guide

The surgical guide was used to perform flapless implant on the six sets of partial edentulous maxilla and mandible models. After stable attachment of the surgical guide to the model, soft tissue punch of 3mm diameter was inserted into the sleeve of the surgical guide in position of implant and rotated to remove the silicon gum.

Drilling was done to 10mm depth using DIO NAVI Surgical Kit (Busan, Korea). The first drill used was a $\varnothing 2.0$ mm drill.

A drill tube for the $\varnothing 2.0$ mm drill was inserted into the sleeve of the surgical guide, and the drill was inserted into the hole at the center of the tube for drilling. The drill tube had guide height of 9 mm (Fig. 9), space of 0.01 mm with the sleeve, and space of 0.02 mm with the drill (Fig. 10). Following the path created by the first drill, $\varnothing 2.8$ mm, $\varnothing 3.3$ mm, $\varnothing 3.8$ mm and $\varnothing 4.3$ mm drills were used in the given order.

All drills have a stop at the top, and drilling was performed at low speed (50 rpm) until this step reached the top of the surgical guide. After drilling, five implants (UF II, DIO Implant, Busan, Korea) were placed (Fig. 11) at the same depth using the same method on each of the six maxilla and mandible models, on both sides of maxillary incisor and mandible molar.

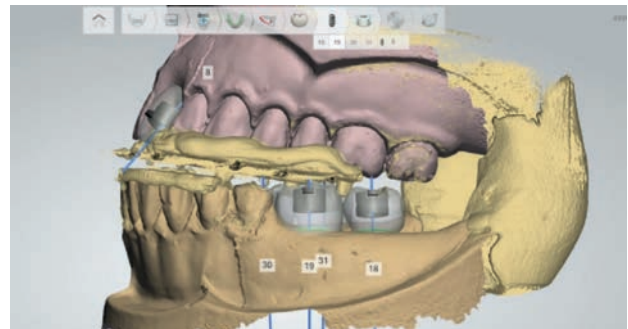


Fig. 6. The merged image of the CBCT scan and the intraoral scan.

4. Accuracy Assessment of Surgical Guide

After implant placement, 2nd CBCT imaging (PointNix, Seoul, Korea) was done in the same way as the first with the reference plate fixed onto the occlusal surface of the model. CBCT images before and after placement were matched using the reference plate, SimPlant software program (Materialise, Leuven, Belgium) was used to find the coordinate values for position of implant in the following way. The line that connects the center of two gutta-percha markers placed horizontally on the plate was set as the X axis, the line that connects the center of two gutta-percha markers placed vertically was set as the Y axis, the intersection point of X and Y axes was set as the O point, and the axis perpendicular to the XOY plane was set as the Z axis (Fig. 12).

The topmost point on the central axis of implant was defined as P (insertion point), and the bottommost point as P' (apex point). The coordinate values of P on the XOY plane, P (x, y) and P' (x', y'), were found. Angles $X\theta$ and $Y\theta$ at which the XOY plane meets the central axis of implant were found (Fig. 13).

Vertical discrepancy was calculated in the Z axis direction of P and P'. Discrepancies of implant distance and angle were calculated in the direction of X axis and Y axis through this process, and discrepancy of vertical depth was calculated in the direction of Z axis (Fig. 14, Fig. 15).

5. Statistical Method

SPSS Ver. 19.0 (SPSS Inc, Chicago, IL, USA) program was used to perform t-test for comparison of horizontal discrepancy and vertical discrepancy. Also, statistical significance level of $P < 0.05$ was used to compare discrepancies of one maxillary implant and four mandibular implants

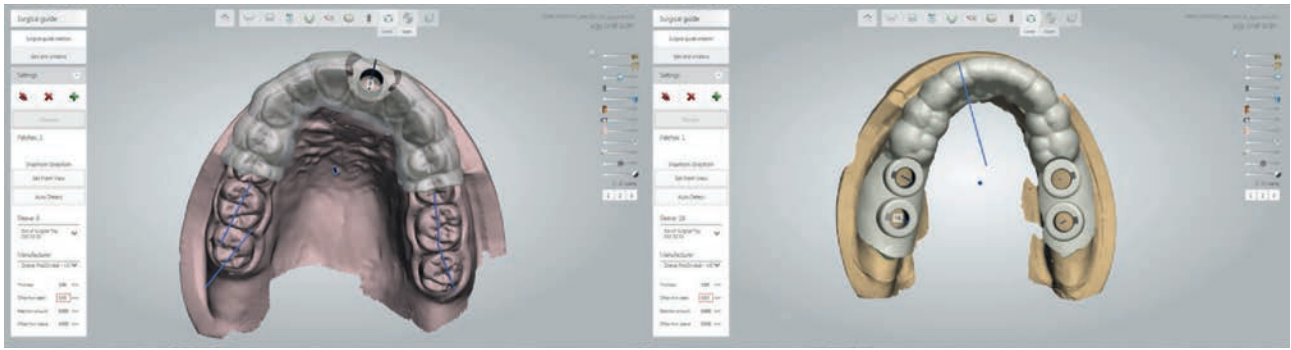


Fig. 7. Virtual surgical guides for the maxilla (A) and mandible (B).

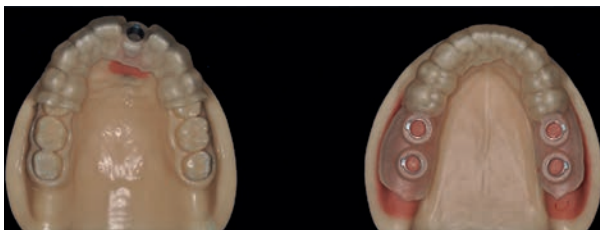

Fig. 8. Surgical guides for the maxilla (A) and mandible (B).




Fig. 9. Guide tube of 9 mm in length.

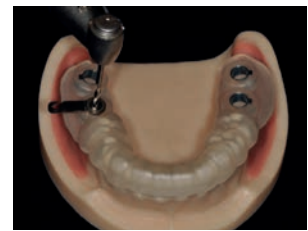

Fig. 10. Drilling through the guide tube with a 2 mm drill.

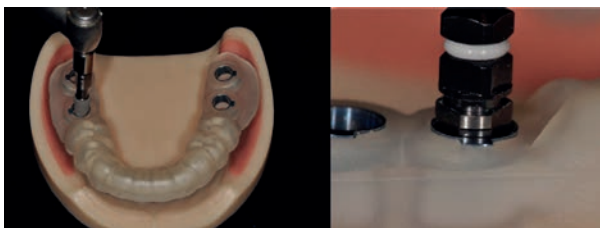

Fig. 11. Surgical guides: Implant placement using the guide (A) and implant connector position at buccal view (B).

Average vertical discrepancy (ΔZ) was 0.44 ± 0.17 mm, and all implants were placed higher than planned vertical height. Discrepancy of vertical height was greater than horizontal discrepancy, and this difference was statistically significant. There was no statistically significant difference between discrepancy of single implant and discrepancy of multiple implants.

Results

All surgical guides made were very stable when attached to the models (Fig. 16). Table 1 presents discrepancies of distance, angle and vertical height of implants in the direction of X axis, Y axis and Z axis.

Average distance discrepancy (ΔX , ΔY) at the top point of implant was 0.27 ± 0.11 mm in the direction of X axis and 0.29 ± 0.13 mm in the direction of Y axis. Average distance discrepancy ($\Delta X'$, $\Delta Y'$) at the bottom point was 0.11 ± 0.10 mm in the direction of X axis and 0.14 ± 0.10 mm in the direction of Y axis. Average angle discrepancy ($\Delta X\theta$, $\Delta Y\theta$) was $0.26 \pm 0.10^\circ$ in the direction of X axis and $0.26 \pm 0.11^\circ$ in the direction of Y axis.

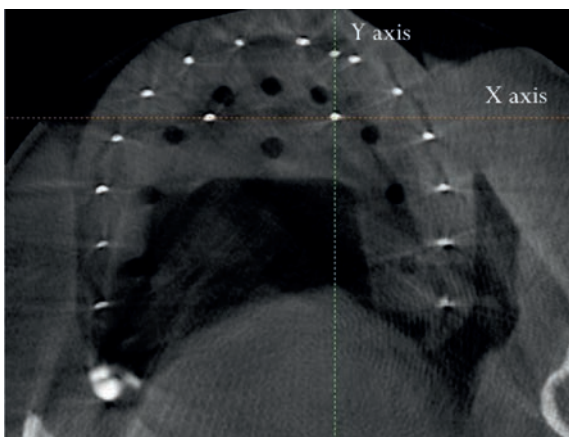


Fig. 12. The X- and Y-axis on the CBCT image.

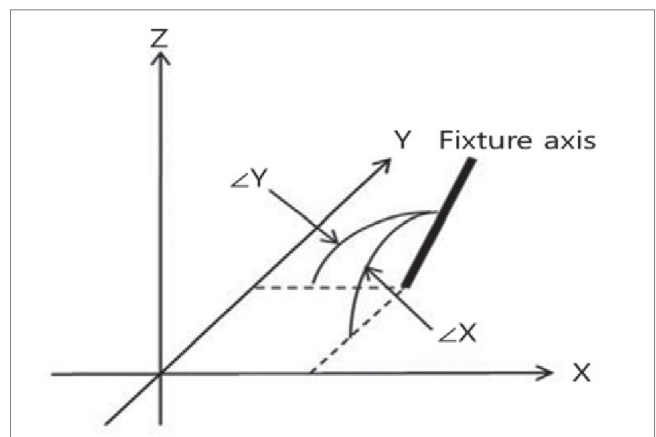


Fig. 13. These illustrations show the procedure used to determine the position and angle of the virtual implant. The insertion point P (X, Y) and apex point P' (X', Y') is determined by the crossing point between the axis of the virtual implant and the XOY-plane. $\angle X$ ($X\theta$) and $\angle Y$ ($Y\theta$) are defined as the angles from the X- and Y- axes, respectively.

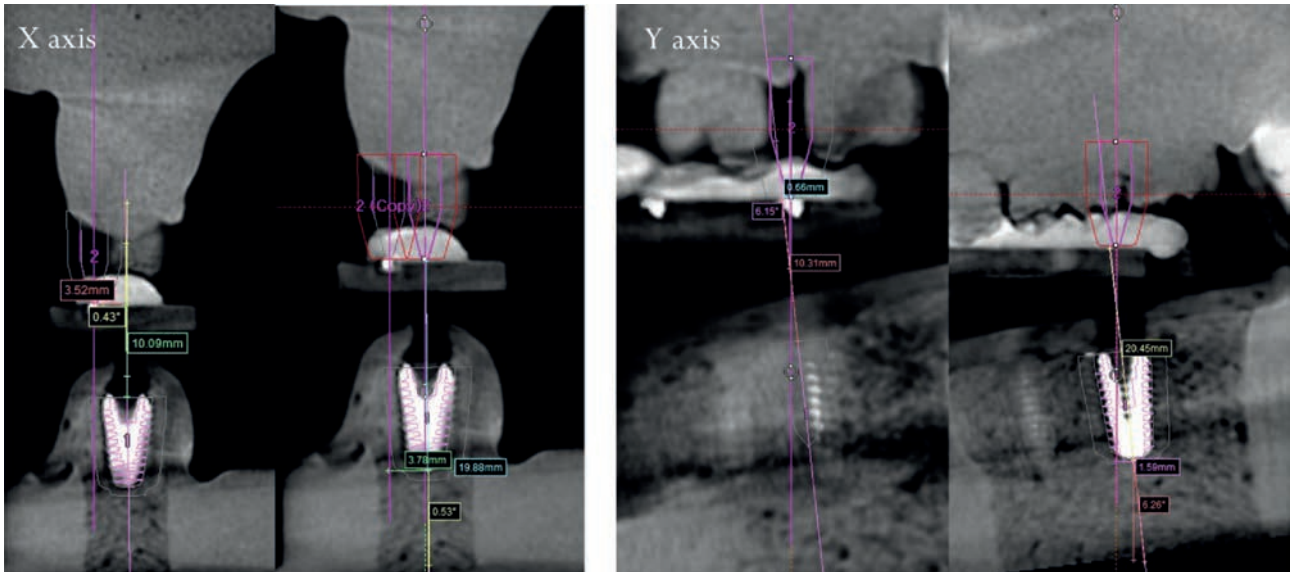


Fig. 14. Position and angulation of the implant on the CBCT image.

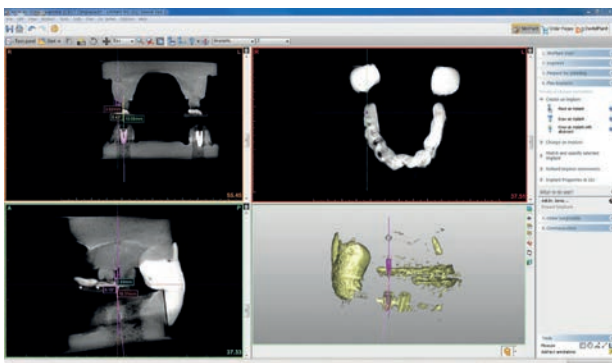


Fig. 15. Position and angulation of the implant on the Simplant software.

Discussions

In this study, digital impression taking was used to scan and obtain digital image of teeth and mucous membrane using an oral scanner. This removes the need for the conventional impression taking process and plaster model. Also, there is no discomfort of having to send plaster model or impression material via postal mail. Making the surgical guide using digital impression has an advantage of shortening time of manufacture, as digital data are sent through the internet. In addition, the manufacturer and operator can easily share real-time information about the patient.¹⁰

Various methods were used and continuously developed to make surgical guides. These methods are as follows. The first method is to manually make a radiation guide and convert it into a surgical guide (manual method).^{8,9} This method makes a radiation guide based on a resin template with a reference marker in a plaster model obtained by

taking oral impression of a patient, takes a CBCT image after attaching the radiation guide to the inside of the mouth, obtains position information of implant based on the market on the CBCT image, and fixes the sleeve onto position of the radiatino guide to convert it into a surgical guide.

The second method is to manually make a radiation guide and then make a surgical guide by stereolithography (stereolithography method).⁴⁻⁷ This method makes a radiation guide based on a resin template with a reference market in the plaster model obtained by taking oral impression of a patient, takes a CBCT image after attaching the radiation guide to the inside of the mouth, and takes an image of the radiation guide once again.

These two CBCT images are overlapped on the reference marker to design a surgical guide. A 3D printer (stereolithography) is used to make the actual surgical guide. The third method is a method of making a surgical guide using scanned image of plaster model, CBCT image and CAD/CAM (partial digital method).

This method uses an image created by overlapping impression image of a plaster model and CBCT image to design a surgical guide and makes the surgical guide using a 3D printer.

The fourth method is a method of making a surgical guide using oral scanning image, CBCT image and CAD/CAM (full digital method).¹¹⁻¹³ This method uses an image created by overlapping two digital data, oral scanning image and CBCT image, without a plaster model to design a surgical guide and makes the surgical guide using a 3D printer. Most of existing studies reviewed used the manual method or stereolithography method to make surgical guides.⁴⁻⁹ According to data on discrepancies of surgical guides made using the methods presented, average position displacement was 1.22 mm at the top of implant and average angle discrepancy was 4.9°.⁴⁻⁹

In this study, the full digital method was used to make the surgical guides without using impression material and plaster model. Average discrepancy of the surgical guides was 0.28 mm and 0.11 mm at the top and bottom of implant, and average angle discrepancy was 0.26°. The results showed much higher accuracy compared to surgical guides reported in the existing studies. The primary causes of high accuracy are reduction of discrepancy during manufacture of the surgical guides and reduction of surgical discrepancy related to implant placement. When the surgical guides are made using the full digital method without using impression material and plaster model, discrepancy caused by deformation from hardening of impression material and plaster is removed, and there is no discrepancy from the process of making radiation guide.^{7,14-19}

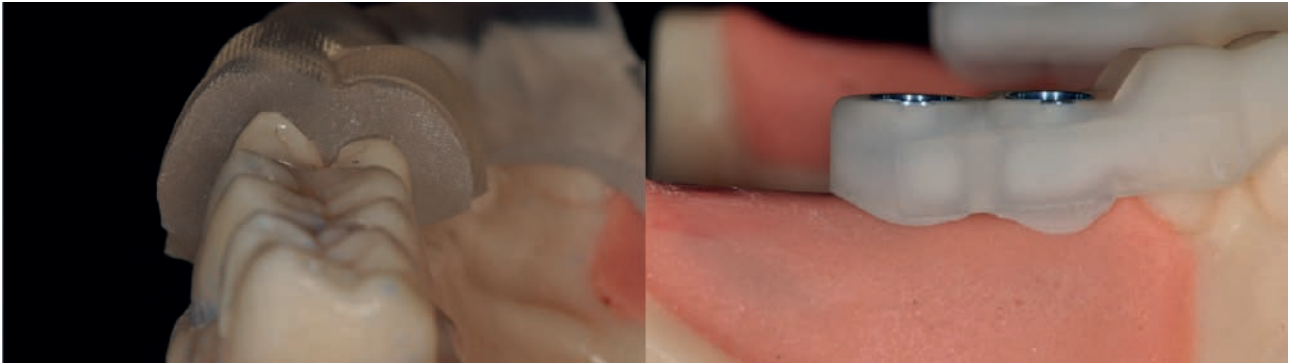


Fig. 16. Surgical guides on the resin maxilla (A) and mandible models (B).

Table 1. Determine the position and angle of the virtual implant at X, Y, Z-axes. The insertion point P (X, Y) and apex point P' (X', Y') are determined by the crossing point between the axis of the virtual implant and the XOY-plane. $\angle X$ ($X\theta$) and $\angle Y$ ($Y\theta$) are defined as the angles from the X- and Y-axes, ΔZ is defined as vertical discrepancy

Discrepancy	ΔX (mm)	$\Delta X'$ (mm)	ΔY (mm)	$\Delta Y'$ (mm)	$\angle X\theta(^{\circ})$	$\angle Y\theta(^{\circ})$	ΔZ (mm)
Mean	0.27	0.11	0.29	0.14	0.26	0.26	0.44
SD	0.11	0.10	0.13	0.08	0.10	0.11	0.17

Average vertical discrepancy was 0.44 ± 0.17 mm, and all implants were placed above planned vertical height. This vertical discrepancy probably resulted from the process of making the surgical guides using the full digital method. In other words, discrepancies that occur during the processes of oral scanning, image matching and making actual surgical guide were combined to result in vertical discrepancy during the surgery. This vertical discrepancy leads to plus vertical discrepancy, which means that implant is not placed as deep as planned out. Therefore, when performing implant placement using a surgical guide made by the full digital method, such vertical discrepancy needs to be corrected during or immediately after implant placement.

Conclusions

The results of this study showed that implant can be placed accurately according to position and angle planned out by performing implant placement with a surgical guide made using digital oral scanning without a plaster model.

ORCID

References

- Jeong SM, Choi BH, Xuan F, Kim HR. Flapless implant surgery using a mini-incision. *Clin Implant Dent Relat Res* 2012;14:74-9.
- Sclar AG. Guidelines for flapless surgery. *J Oral Maxillofac Surg* 2007;65:20-32.
- Terzioğlu H, Akkaya M, Ozan O. The use of a computerized tomography-based software program with a flapless surgical technique in implant dentistry: a case report. *Int J Oral Maxillofac Implants* 2009;24:137-42.
- DiGiacomo GA, Cury PR, de Araujo NS, Sendyk WR, Sendyk CL. Clinical application of stereolithographic surgical guides for implant placement: preliminary results. *J Periodontol* 2005;76: 503-7.
- Ruppini J, Popovic A, Strauss M, Spüntrup E, Steiner A, Stoll C. Evaluation of the accuracy of three different computer-aided surgery systems in dental implantology: optical tracking vs. stereolithographic splint systems. *Clin Oral Implants Res* 2008;19:709-16.
- Van Assche N, van Steenberghe D, Guerrero ME, Hirsch E, Schutyser F, Quirynen M, Jacobs R. Accuracy of implant placement based on pre-surgical planning of three-dimensional cone-beam images: a pilot study. *J Clin Periodontol* 2007;34:816-21.
- van Steenberghe D, Naert I, Andersson M, Brajnovic I, Van Cleynenbreugel J, Suetens P. A custom template and definitive prosthesis allowing immediate implant loading in the maxilla: a clinical report. *Int J Oral Maxillofac Implants* 2002;17:663-70.
- Kalt G, Gehrke P. Transfer precision of three-dimensional implant planning with CT assisted offline navigation. *Int J Comput Dent* 2008;11:213-25.
- Nickenig HJ, Eitner S. Reliability of implant placement after virtual planning of implant positions using cone beam CT data and surgical (guide) templates. *J Craniomaxillofac Surg* 2007; 35:207-11.
- Hajeer MY, Millett DT, Ayoub AF, Siebert JP. Applications of 3D imaging in orthodontics: part II. *J Orthod* 2004;31:154-62.
- Flügge TV, Nelson K, Schmelzeisen R, Metzger MC. Three-dimensional plotting and printing of an implant drilling guide: simplifying guided implant surgery. *J Oral Maxillofac Surg* 2013;71:1340-6.
- Lee CY, Ganz SD, Wong N, Suzuki JB. Use of cone beam computed tomography and a laser intraoral scanner in virtual dental implant surgery: part 1. *Implant Dent* 2012;21:265-71.
- Stapleton BM, Lin WS, Ntounis A, Harris BT, Morton D. Application of digital diagnostic impression, virtual planning, and computer-guided implant surgery for a CAD/CAM-fabricated, implant-supported fixed dental prosthesis: a clinical report. *J Prosthet Dent* 2014;112:402-8.
- Torassian G, Kau CH, English JD, Powers J, Bussa HI, Marie Salas-Lopez A, Corbett JA. Digital models vs plaster models using alginate and alginate substitute materials. *Angle Orthod* 2010;80:474-81.
- Akyalcin S, Cozad BE, English JD, Colville CD, Laman S. Diagnostic accuracy of impression-free digital models. *Am J Orthod Dentofacial Orthop* 2013;144:916-22.
- Horwitz J, Zuabi O, Machtei E. Radiographic changes around immediately restored dental implants in periodontally susceptible patients: 1-year results. *Int J Oral Maxillofac Implants* 2008;23: 531-8.
- Jung RE, Schneider D, Ganeles J, Wismeijer D, Zwahlen M, Hämmerle CH, Tahmaseb A. Computer technology applications in surgical implant dentistry: a systematic review. *Int J Oral Maxillofac Implants* 2009;24:92-109.

DIO IMPLANT